

CHIEF EDITOR'S NOTE: This article is the 32nd of 36 that will be published in 2000 for which a total of up to 36 Category 1 CME credits can be earned. Instructions for how credits can be earned appear on the last page of the Table of Contents.

## Irreversible Maternal Brain Injury During Pregnancy: A Case Report and Review of the Literature

Deborah M. Feldman, MD,\* Adam F. Borgida, MD,† John F. Rodis MD‡  
and Winston A. Campbell, MD‡

\*Clinical Instructor, †Assistant Professor, ‡Professor, Department of Obstetrics and Gynecology, Division of Maternal-Fetal Medicine, University of Connecticut Health Center, Farmington, Connecticut

**Maternal brain death or massive injury leading to persistent vegetative state during pregnancy is a rare event. Since 1979, 11 cases, including the current one, of irreversible maternal brain damage in pregnancy have been reported. In all but one, the pregnancies were prolonged with a goal of achieving delivery of a viable infant. Current advances in medicine and critical care enable today's physician to offer prolonged life-support to maximize the chances for survival in the neonate whose mother is technically brain dead. We present a case at our institution and review all previously published cases in the English literature for comparison as well as make management recommendations.**

**Target Audience:** Obstetrics & Gynecologists, Family Physicians

**Learning Objectives:** After completion of this article, the reader will be able to outline the legal and ethical considerations of a patient with fatal maternal brain injury, list the common complications in a patient with fatal maternal brain injury, and describe the management of these complications.

### INTRODUCTION

Maternal brain death or persistent vegetative state caused by irreversible brain damage in pregnancy is uncommon. Successful prolongation of pregnancy in women who have suffered severe brain injury or brain death to preserve the life of the fetus has been described. Our review identified eight reported cases of maternal brain death in pregnancy and two cases of persistent vegetative state associated with irreversible brain injury. All of these cases represented significant challenges in the areas of intensive care, obstetrics, and ethics.

Reprints not available.

Correspondence to: Deborah M. Feldman, MD, Division of Maternal-Fetal Medicine, Administrative Contact: Bonnie Voight, University of CT Health Center, MC-2950, 263 Farmington Ave, Farmington, CT 06030-2950. Email: dfeldman@nso2.uchc.edu

The authors have disclosed no significant financial or other relationship with any commercial entity.

Advances in life-support technology and critical care have enhanced the maintenance of vital organ systems in patients diagnosed with brain death or persistent vegetative state. These techniques have been used for short-term maintenance of brain-dead individuals undergoing organ transplantation. Pregnancy is another clinical scenario where there may be a benefit to continuing life support to prolong a pregnancy and increase the chance for fetal survival. Although it is generally believed that cardiovascular collapse occurs within days after brain death, somatic survival has been described for weeks in cases where the goal has been to prolong pregnancy and deliver a viable infant. Our case represents only the second report where organ transplantation was achieved after a successful pregnancy outcome in a mother with irreversible brain damage. We provide a comprehensive review of similar reported cases and discuss the medical, obstetric, and ethical issues surrounding

these cases. Moreover, we recommend a protocol for managing such patients.

### Case Report

A previously healthy 23-year-old single woman, G2P1001, presented at 16 weeks' gestation with acute onset of right-sided weakness and aphasia. Computed tomography at the referring hospital revealed a large area of ischemia in the left cerebral hemisphere, and the patient was transferred by air ambulance to our institution for additional management. On admission, the patient was afebrile with stable vital signs. Her neurologic examination was remarkable for left preferential gaze and the absence of spontaneous movement or strength in her right upper and lower extremities. She was aphasic but responded by withdrawal to painful stimulus on the left side. The patient was initially admitted to a medical floor. Magnetic resonance angiography was performed and revealed complete occlusion of the left middle cerebral artery. Before admission, her pregnancy had been uneventful. She had a normal maternal serum screen for aneuploidy and neural tube defects at 15 weeks. A targeted ultrasound was obtained on admission and revealed an intrauterine pregnancy at 16 weeks' gestation with no fetal or placental anomalies.

Because the patient was transferred several hours after the initial diagnosis had been made, thrombolytic therapy was not initiated. The patient was managed expectantly. During the next 12 hours, the patient's neurologic status worsened with development of fixed and dilated pupils and respiratory depression. She was intubated for respiratory failure and transferred to the intensive care unit on the evening of admission. Evaluation for possible causes of the thromboembolic event included an echocardiogram and hematological investigation for hereditary thrombophilia and antiphospholipid antibody syndrome. All of these laboratory values were within normal limits. A magnetic resonance image (MRI) of the brain on day 2 of hospitalization revealed significant herniation of the brainstem, and the patient ceased to have spontaneous respirations. Her neurologic condition deteriorated, and her poor prognosis was discussed with the family. They wished to continue aggressive life support to maintain the pregnancy as long as possible.

The patient's 100-day hospital course was complicated by medical problems involving multiple organ systems. Among these were panhypopituitarism treated with thyroid hormone, hydrocortisone, and

dexamethasone. Intranasal 1-deamino 8-d-arginine vasopressin or desmopressin acetate (DDAVP, Rhône-Poulenc Rorer Pharmaceuticals Inc, Collegetown, PA) was initiated for treatment of diabetes insipidus. She required pressors for severe hypotension during the first week of her admission. The blood pressure then stabilized for several weeks followed by a period of lability in her systolic blood pressure. Hyperthermia developed with associated sinus tachycardia in the 120 to 140 beats per minute range. Treatment with acetaminophen and a cooling blanket was required. A tracheostomy was performed on the 18th hospital day, and multiple courses of antibiotics were used to treat recurrent episodes of pneumonia and sinusitis. Feeding was initiated with a nasogastric tube early in her hospital course followed by placement of a jejunostomy tube on hospital day 20. Neurologically, the patient remained completely unresponsive but did not meet the criteria for brain death because of intermittent grand mal seizures that required therapy with repeated doses of intravenous diazepam. A combined meeting of the adult and infant ethics committees convened to review the case and offer guiding management principles.

The patient's obstetric status remained stable throughout her hospital course. Serial growth ultrasounds were performed at 20, 24, and 28 weeks of gestation and showed normal fetal growth. Beta-methasone therapy to promote fetal lung maturity as well as daily fetal heart rate and contraction monitoring were initiated at 24 weeks of gestation (beta-methasone has not been approved by the U.S. Food and Drug Administration for this indication).

At 31 weeks of gestation, the patient developed severe grand mal seizure activity that was difficult to control medically. This was associated with severe systolic hypertension in the 160 to 170 mm Hg range, and the decision was made to perform a cesarean delivery. A viable male infant weighing 1506 gm was delivered without complication. Apgar scores were 5 and 8 at 1 and 5 minutes, respectively. Arterial cord pH was 7.33. The following day, the patient was brought to the operating room where life support measures were discontinued. There were no spontaneous respirations, and after 37 minutes of apnea she was pronounced dead. An organ harvest including kidneys, eyes, and heart valves was performed.

The infant was admitted to the neonatal intensive care unit and was treated with surfactant and nasal continuous positive airway pressure for respiratory distress syndrome. Apnea of prematurity, hyperbilirubinemia, and a patent ductus arteriosus also complicated his neonatal course. He was discharged in

stable condition on day 76 of life in the custody of his maternal grandmother. He is currently alive and well at 18 months of age.

### LITERATURE REVIEW

There have been several reported cases of successful pregnancy outcomes after devastating maternal brain injury (1–10). A summary of these cases is presented in Table 1. Of the 11 reported cases, 4 have involved maternal persistent vegetative state, whereas 7 report maternal brain death. The criteria used to define brain death varied from case to case. Two reports (2, 5) define maternal brain death using the Harvard criteria (6, 12). Other cases have defined brain death using electroencephalographic silence (7), a clinical neurologic examination including the absence of reflexes (9), or a combination of both EEG and neurologic findings (3, 6, 10).

Of the 10 cases in which an attempt was made to prolong the pregnancy, the average latency period between time of injury and time of delivery was 79.5 days (range 1–189 days), and the average gestational age at the time of delivery was 30.5 weeks (range 26–35 weeks). All deliveries were preterm, and all but one were performed by cesarean. Indications for delivery were variable, and included fetal distress (2, 7, 8) intrauterine growth restriction (5), preterm labor (1, 3, 9), documented fetal lung maturity (10), and severe maternal hypotension (4).

### LEGAL AND ETHICAL CONSIDERATIONS

There are many legal and ethical questions that arise in cases where a pregnant woman is unable to make decisions regarding the care of herself or her fetus. Because few women are prepared for such a devastating event, advanced directives of their wishes in pregnancy are extremely rare. Such cases require a surrogate decision-maker, which is generally assigned to the next of kin. In our case, the patient was unmarried but cohabited with the father of the baby. The patient's mother was assigned to be the patient's surrogate for making decisions about health care, because cohabitation does not constitute marriage in our state. Because this law varies from state to state, legal inquiries should be made to help guide decision-making. One can perceive how such cases can be associated with major conflict between surrogates and other members of the family and care providers, adding more stress to an already difficult situation.

In addition to the legal burden of assigning a surrogate, there are ethical considerations regarding the decision to continue/terminate a pregnancy, or prolong intensive life-support measures for the sake of the fetus. Such decisions may be influenced by gestational age at the time of brain injury, although our review of the literature documents several cases where extremely premature pregnancies were prolonged successfully. Finnerty et al. (11) recommends using a family-centered approach focusing on maternal autonomy and considering any previously expressed wishes of the patient. Extensive counseling and education regarding the prognosis of both the patient and the fetus should be offered so that the family can make an informed decision concerning additional life support. A combined meeting of medical, obstetric, neonatal, social work, and ethical staff as well as family members should be undertaken to discuss various issues about the patient's care and formulate a plan of care based on the family's wishes.

Although several authors have recommended that no life support should be offered to the mother before 24 weeks of gestation (2, 10), our case and others suggest that successful outcomes can occur even when the injury occurs much earlier in pregnancy.

### MEDICAL CONSIDERATIONS

Table 1 includes the maternal medical complications in the 11 patients with fatal maternal brain injury. Among these complications were thermolability or hyperthermia (8/11) pituitary failure (5/11), infectious morbidity (7/11), and cardiovascular instability/hypotension (6/11). These are common complications after brain death and are often associated with complete cardiovascular collapse within days to weeks of making the diagnosis (5, 6).

Aggressive respiratory and cardiovascular support are invariably required, and recommendations for mechanical ventilation and treatment of hypotension in pregnancies complicated by fatal maternal brain damage have been previously published (5). According to these suggested guidelines, mechanical ventilation should start with a tidal volume of 10 to 15 ml/kg with a fraction of inspired oxygen (FiO<sub>2</sub>) of 1.0. The FiO<sub>2</sub> should then be decreased to <0.6 while maintaining oxygen saturation at 90 percent. Positive end-expiratory pressure may be used if needed to keep arterial oxygen tension >60 mm Hg.

Hypotension should be treated with intravenous dopamine (2–5 μg/kg per minute) with titration to keep a mean arterial pressure of 80 to 110 mm Hg.

TABLE 1 Summary of reported cases of maternal irreversible brain damage with pregnancy and neonatal outcomes\*

Case	Primary Author	Cause of Injury	GA @ Time of Injury (weeks)	Duration of Life Support (days)	GA @ Delivery (weeks)	Mode of Delivery	Neonatal Outcome	Maternal Medical Complications
1	Sampson and Peterson (1)* (1979)	TBI (s/p MVA)	6	189	33	Forceps	1640 gm	Malnutrition, hyperthermia
2	Dillon et al. (2)* (1982)	CVA	18	10	N/A	N/A	Apgars 3,6 RDS	Hyperthermia
3	Dillon et al. (2)† (1982)	Meningitis	23	24	26	C/S	930 gm	Thermovariability, carbo. intolerance, DI, vasomotor instability
4	BenAderet et al. (3)* (1984)	TBI (s/p MVA)	17	126	35	C/S	d/c home @ 3 mos 2450 gm	Hyperthermia, recurrent UTIs, tracheal infections
5	Heikkinen et al. (4)† (1985)	SAH, ICH	21	70	31	C/S	Apgars 3,9 d/c day #17 1600 gm	Thermovariability, pnuemomia, hypotension, bacteremia, DI, panyhypopituitarism
6	Field et al. (5)† (1988)	CNS mass	22	63	31	C/S	Apgars 6,7 A+W @ 8 mos 1440 gm	Thermovariability, hypotension panyhypopituitarism DI
7	Bernstein et al. (7)† (1989)	TBI (s/p MVA)	15	107	32	C/S	Apgars 8,8 A+W @ 18 mos 1555 gm	Thermovariability, panyhypopituitarism pneumonia
8	Vives et al. (8)† (1995)	Meningitis	27	1	27	C/S	Apgars 6,9 1150 gm	Hypotension, sepsis, DIC.
9	Catanzarite et al. (9)† (1997)	ICH	25	25	28.5	C/S	Apgars 7,10 d/c home @ 2 mos 1315 gm	Hypotension, panyhypopituitarism DI pneumonia
10	Lewis and Vidovich (10)† (1997)	SAH	25	55	31	C/S and organ donation	Apgars 3,7 d/c home day 34 N/A	Hypotension, DI, bacteremia
11	Feldman et al.* (present case)	CVA	15	100	31	C/S and organ donation	1506 gm	Panyhypopituitarism, DI, hyperthermia, hypertension, seizures, pneumonia, sinusitis
							Apgars 5,9 A+W @ 18 mos	

\* Cases involving maternal patients in vegetative state.

† Cases involving maternal brain death.

‡ Maternal vegetative state, † maternal brain death, RDS = respiratory distress syndrome, TBI = traumatic brain injury, GA = gestational age, MVA = motor vehicle accident, DIC = disseminated intravascular coagulopathy, d/c = discharge, CVA = cerebrovascular accident, ICH = intracranial hemorrhage, SAH = subarachnoid hemorrhage, CNS = central nervous system, DI = diabetes insipidus, C/S = cesarean section, A+W = alive and well. N/A = not available.

Dobutamine may be added at an infusion rate of 2.5 to 15.0  $\mu\text{g}/\text{kg}$  per minute if needed. Warming or cooling blankets may be used to treat thermovariability. Endocrine abnormalities are also common among these patients, and should be treated with appropriate hormone replacement including desmopressin acetate, thyroxine, and corticosteroids to treat diabetes insipidus, thyroid dysfunction, and adrenal failure, respectively. Nutritional support should be initiated as soon as possible using enteral tube feedings or parenteral nutrition. Because of the high risk of various infections in these patients, frequent cultures of urine, blood, sputum, and lines are recommended. Our patient required multiple courses of antibiotics for pneumonia and sinusitis.

In general, meticulous multidisciplinary intensive care is required to maintain somatic survival, inevitably amounting to tremendous cost. Pregnancy is one instance in which such vigorous management of the fatally ill patient may be justified.

### OBSTETRIC CONSIDERATIONS

Patients undergoing aggressive life support for the sole purpose of maintaining a pregnancy require intensive obstetric as well as medical care. Previous reported cases make sparse recommendations regarding obstetric care and surveillance as the pregnancy continues. Because of the ethical dilemmas associated with the decisions surrounding maternal brain death, we recommend 1) a maternal serum screen for chromosomal abnormalities and neural tube defects, and 2) a targeted ultrasound to rule out any congenital fetal anomalies. The results of these investigations may impact decisions made by the family. If the patient is at high risk for a chromosomal abnormality either based on maternal age, serum screening, or ultrasound findings, consideration should be given to amniocentesis for karyotyping.

Catanzarite et al. (9) reported the need for initial aggressive tocolysis with magnesium sulfate and indomethacin for preterm labor. The pregnancy was maintained for several weeks until amniocentesis revealed chorioamnionitis with *Torulopsis glabrata*. Although most other reports do not indicate similar obstetric complications, these pregnancies are clearly high-risk and should be managed at a tertiary center where there are appropriate neonatal facilities. In addition, serial ultrasounds for fetal growth should be performed on a regular basis, as intrauterine growth restriction has been reported (5). In several of the reported cases, non-reassuring fetal heart rate tracings were the indication for delivery. For this reason,

these patients should have frequent assessment of fetal well-being, including daily fetal heart rate monitoring after 24 weeks of gestation.

Finally, timing and mode of delivery must be established. Ten of the 11 cases reported delivery before 34 weeks' gestation. However, in the absence of other complications requiring delivery, fetal lung maturity should be documented by amniocentesis between 34 and 36 weeks of gestation. All but one report in the literature describes cesarean delivery. Because of possible fetal complications associated with a trial of labor and a likely need for operative assistance with forceps or vacuum, we feel that cesarean birth provides the safest and most expeditious mode of delivery for the fetus.

### NEONATAL CONSIDERATIONS

Although long-term data on each of the reported cases were not available, cases where an attempt was made to prolong pregnancy resulted in delivery at a mean gestational age of 30.5 weeks with a mean birth weight of 1509 gm. Complications of prematurity such as respiratory distress syndrome, hyperbilirubinemia, and apnea of prematurity were noted in our case. Detailed accounts of neonatal courses were not available in each of the prior cases. However, because all cases to date have resulted in premature delivery, families need to be counseled about possible short- and long-term complications of preterm delivery. Such information is important when making decisions regarding prolongation of life support. In most of the cases reported, fetal survival would not have been possible if delivery occurred immediately after the maternal brain injury because of the early gestational age.

### ORGAN DONATION

Although complicated from a medical and obstetrical standpoint, cases in which the vital organs of an irreversibly brain-damaged mother are maintained to support a fetus should be considered for organ donation. This consideration may add significant ethical burden to the patient's family and health care providers, as multiple medical problems over time may jeopardize the organs to be transplanted. The family should be counseled by intensivists, perinatologists, neonatologists, and members of a transplant team to understand the implications of their decision.

Our case represents only the second one in which select organs were successfully harvested. Lewis and Vidovich (10) reported a case of maternal brain death

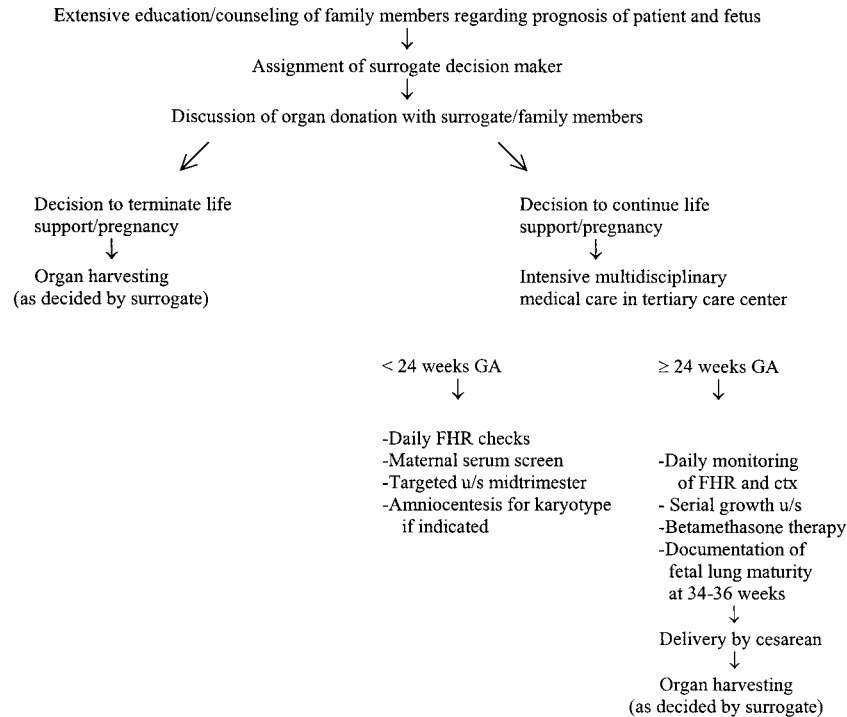


Fig. 1. Algorithm for recommended management of cases of irreversible maternal brain injury. u/s = ultrasound, GA = gestational age, FHR = fetal heart rate, ctx = contractions.

in which the pregnancy was maintained for 54 days. Delivery occurred by cesarean immediately followed by harvesting of the patient's heart, kidneys, pancreas, and both kidneys. At the time of publication, all four organ recipients were doing well with no complications. In our case, the patient did not meet the requirement of brain death because of seizure activity both clinically and by electroencephalogram. Therefore, she was brought to the operating room where respiratory support was discontinued and an organ harvest in a non—heart-beating donor was performed.

There continues to be an overwhelming demand for organs compared with the small number of patients considered suitable for donation. Young, otherwise healthy, pregnant women who have irreversible fatal brain damage (and especially those who meet the strict criteria for brain death) should be considered candidates for organ transplantation regardless of the decision to prolong the pregnancy. This issue should be addressed with the family early in the patient's hospitalization so that appropriate planning and matching may take place.

### RECOMMENDED MANAGEMENT

Based on review of all the reported cases of irreversible maternal brain injury in pregnancy, we have

proposed an algorithm for management of such patients (Fig. 1).

### CONCLUSION

Fortunately, devastating maternal brain injury during pregnancy is rare. This review summarizes several successful outcomes that have been achieved in such cases. Our case demonstrates many of the same medical, obstetric, and ethical features described in previously reported cases of maternal brain damage. We recommend that such cases be managed with an intensive multidisciplinary approach using expertise in the areas of neurology, critical care, maternal-fetal medicine, neonatology, ethics, and social work.

### REFERENCES

1. Sampson MB, Peterson LP. Post-traumatic coma during pregnancy. *Obstet Gynecol* 1979;53:2S-3S.
2. Dillon WP, Lee RV, Tronolone MJ et al. Life support and maternal brain death during pregnancy. *JAMA* 1982;248:1089-1091.
3. BenAderet N, Cohen I, Abramowicz JS. Traumatic coma during pregnancy with persistent vegetative state. *Br J Obstet Gynaecol* 1984;91:939-941.
4. Heikkinen JE, Rinne RI, Alahuta SM et al. Life support for 10 weeks with successful fetal outcome after fatal maternal brain damage. *BMJ* 1985;290:1237-1238.

5. Field DR, Gates EA, Creasy RK et al. Maternal brain death during pregnancy. *JAMA* 1988;260:816-822.
6. Black PM. Brain death. *N Engl J Med* 1978;299:338-344, 393-401.
7. Bernstein IM, Watson M, Simmons GM et al. Maternal brain death and prolonged fetal survival. *Obstet Gynecol* 1989;74:434-437.
8. Vives A, Carmona F, Zabala E et al. Maternal brain death during pregnancy. *Int J Gynecol Obstet* 1996;52:67-69.
9. Catanzarite VA, Willms DC, Holdy KE et al. Brain death during pregnancy: Tocolytic therapy and aggressive maternal support on behalf of the fetus. *Am J Perinatol* 1997;14:431-434.
10. Lewis DD, Vidovich RR. Organ recovery following childbirth by a brain-dead mother: A case report. *J Transpl Coord* 1997;7:103-105.
11. Finnerty JJ, Chisholm CA, Chapple H et al. Cerebral arteriovenous malformation in pregnancy: Presentation and neurologic, obstetric, and ethical significance. *Am J Obstet Gynecol* 1999;181:296-303.
12. Bernat JL, Culver CM, Gert B. On the definition and criterion of death. *Ann Intern Med* 1981;94:389-394.